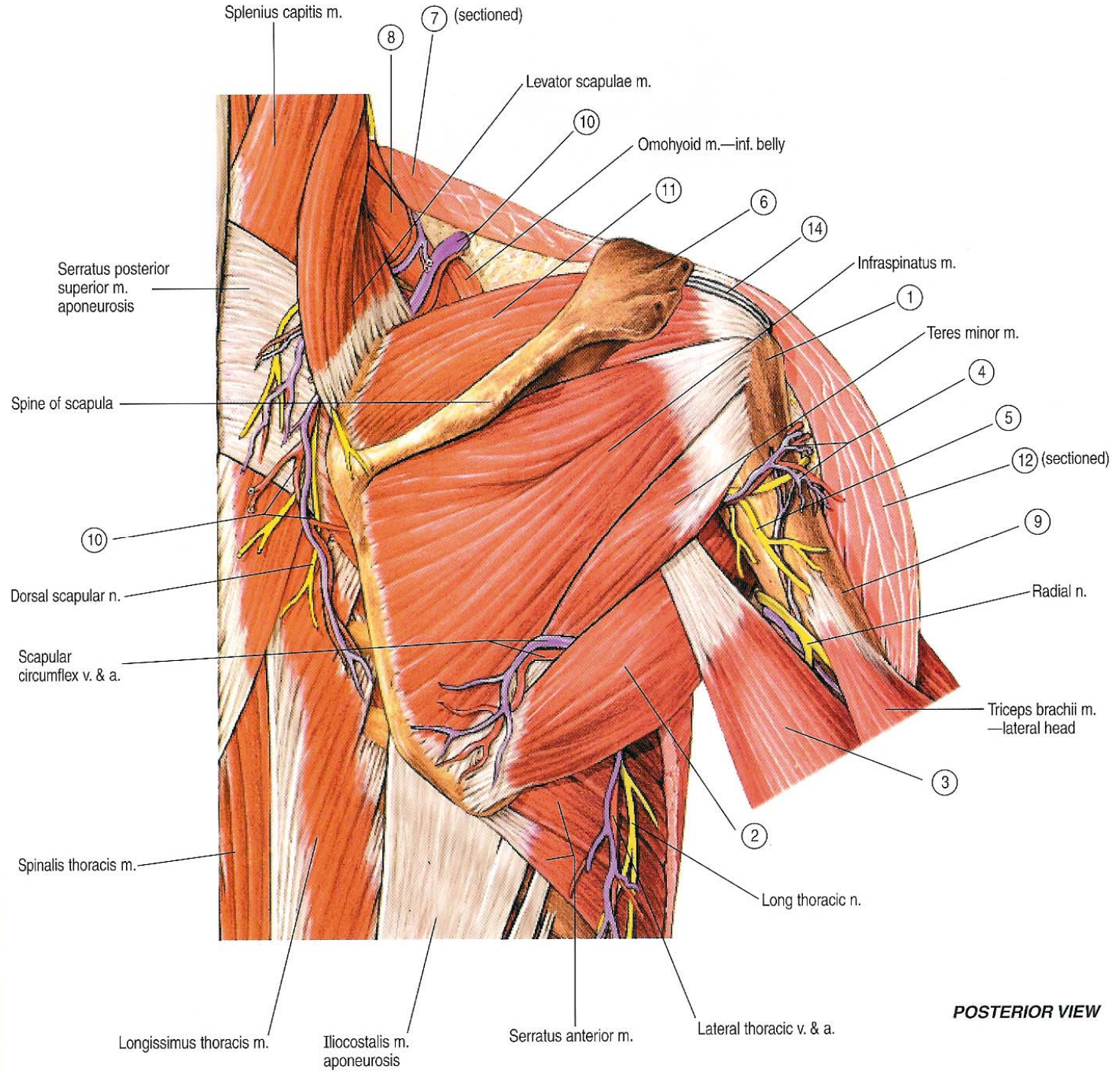


بِسْمِ اللَّهِ الرَّحْمَنِ الرَّحِيمِ

# SCAPULAR REGION



**POSTERIOR VIEW**

# Objectives

- **Muscles of the region.**
- **Rotator cuff muscles.**
- **Quadrangular and triangular spaces.**
- **Nerves of the region:**
  - Spinal accessory nerve.
  - Suprascapular nerve.
  - Axillary nerve.
- **Arterial anastomosis:**
  - Around scapula.
  - Around surgical neck of humerus.

# Muscles

- Deltoid.
- Supraspinatus.
- Infraspinatus
- Teres Minor.
- Teres Major.
- Subscapularis.

# Deltoid

## ➤ Origin:

1. ***Anterior fibers*** from the lateral third of the anterior border of the clavicle.
2. ***Middle fibers*** from the lateral border of the acromion process of the scapula.
3. ***Posterior fibers*** from the lower border of the spine of the scapula.

## ➤ Insertion:

Into the deltoid tuberosity, on the middle of the lateral surface of the shaft of the humerus.

# Deltoid

## ➤ Nerve Supply:

From the axillary nerve (C5,6).

## ➤ Action:

**A. Anterior fibers:** flexes and medially rotates the arm.

**B. Posterior fibers:** extends and laterally rotates the arm.

**C. Middle fibers:** abducts the arm till the level of the head (from 15° to 90°).

# Supraspinatus

## ➤ Origin:

From the supraspinous fossa of the scapula.

## ➤ Insertion:

Into the **upper facet** (impression) of the greater tuberosity of the humerus and upper part of the capsule of the shoulder joint.

## ➤ Nerve Supply:

From the suprascapular nerve (C5,6).

## ➤ Action:

**A.** Starts abduction of the arm (from 0° to 15°).

**B.** Stabilizes and supports the shoulder joint (rotator cuff muscle).

# Infraspinatus

## ➤ Origin:

From the infraspinous fossa of the scapula.

## ➤ Insertion:

Into the **middle facet** (impression) of the greater tuberosity of the humerus and posterior part of the capsule of the shoulder joint.

## ➤ Nerve Supply:

From the suprascapular nerve (C5,6).

## ➤ Action:

A. Laterally rotates the arm.

B. Stabilizes and supports the shoulder joint (rotator cuff muscle).

# Teres minor

## ➤ Origin:

From the upper 2/3 of the dorsal lip of the lateral border of the scapula.

## ➤ Insertion:

Into the **lower facet** (impression) of the greater tuberosity of the humerus and posterior part of the capsule of the shoulder joint.

## ➤ Nerve Supply:

From the axillary nerve (C5,6).

## ➤ Action:

A. Laterally rotates the arm.

B. Stabilizes and supports the shoulder joint (rotator cuff muscle).

# Teres major

## ➤ Origin:

The lower third of the posterior surface of the lateral border of the scapula.

## ➤ Insertion:

The medial lip of the bicipital groove of the humerus.

## ➤ Nerve Supply:

Lower subscapular nerve (C5,6).

## ➤ Action:

adducts, extends and medially rotates the arm.

# Subscapularis

## ➤ Origin:

The medial 2/3 of the subscapular fossa of the anterior surface of the scapula and from the inner surface of the subscapular fascia.

## ➤ Insertion:

The lesser tuberosity of the humerus.

## ➤ Nerve Supply:

Upper and lower subscapular nerves (C5,6).

## ➤ Action:

A. It adducts and medial rotates the arm.

B. It stabilizes and supports the shoulder joints.

# Rotator cuff Muscles

- They are the supraspinatus, infraspinatus, teres minor and subscapularis muscle.
- They surround the shoulder joint, except from the inferior aspect (weak point).
- Their tone helps in holding the head of humerus in the glenoid cavity.
- They maintain the stability of the shoulder joint.

# Intermuscular spaces

- They are fascial spaces lying between the muscles in the scapular region.
- They are:
  1. Quadrangular space.
  2. Upper (medial) triangular space.
  3. Lower (lateral) triangular space.

# Quadrangular space

## ■ Boundaries:

- Superiorly: by the subscapularis (from front) or teres minor (from behind) and capsule of shoulder joint.
- Inferiorly: by the teres major muscle.
- Medially: by the long head of triceps.
- Laterally: by the surgical neck of the humerus

## ■ It transmits:

1. Axillary (circumflex) nerve.
2. Posterior circumflex humeral vessels.

# Upper triangular space

## ■ Boundaries:

- Superiorly: by the subscapularis (from front) or teres minor (from behind) and capsule of shoulder joint.
- Inferiorly: by the teres major muscle.
- Laterally: by the long head of triceps.

## ■ It transmits:

1. Circumflex scapular artery.

# Lower triangular space

## ■ Boundaries:

- Superiorly: by the teres major muscle.
- Medially: by the long head of triceps.
- Laterally: by the shaft of the humerus and lateral head of triceps.

## ■ It transmits:

1. Radial nerve.
2. Profunda brachii vessels.

# Scapular Anastomosis

## ■ Forming arteries:

1. **Suprascapular artery** (a branch from the 1<sup>st</sup> part of the subclavian artery) runs on the supraspinous and infraspinous fossae.
2. **Deep branch of superficial cervical artery** (a branch from the 1<sup>st</sup> part of subclavian artery) runs on the medial border of the scapula.
3. **Subscapular artery** (a branch from the 3<sup>rd</sup> part of the axillary artery) runs on the lateral border of the scapula and gives off circumflex scapular artery

## ■ Importance:

- It ensures adequate blood supply to the upper limb during movement of the arm by bypassing any compression between the 1<sup>st</sup> part of the subclavian and the 3<sup>rd</sup> part of the axillary arteries.

**JOINTS**

# Sternoclavicular Joint

- **Type:** Synovial double-plane joint.
- **Articulation:** between the sternal end of the clavicle and the manubrium sterni.
- **Ligaments:** Strong anterior and posterior sternoclavicular ligaments.
- **Articular disc:** flat fibrocartilaginous disc divides the joint into medial and lateral compartments.
- **Accessory ligaments:** Strong costoclavicular ligament.

# Sternoclavicular Joint

## ■ Movements:

- Forward and backward movement of the clavicle (takes place in the medial compartment of the joint).
- Elevation and depression of the clavicle (takes place in the lateral compartment of the joint).

1. **Forward movement:** by serratus anterior.
2. **Backward movement:** by trapezius and rhomboids.
3. **Elevation:** by trapezius, sternocleidomastoid, levator scapulae and rhomboids.
4. **Depression:** by pectoralis minor and subclavius.

# Acromioclavicular Joint

- **Type:** Synovial plane joint.
- **Articulation:** between the lateral end of the clavicle and the acromion process of scapula.
- **Ligaments:** Strong superior and inferior acromioclavicular ligaments.
- **Accessory ligaments:** Very strong coracoclavicular ligament.
- **Nerve supply:** Suprascapular nerve.
- **Movements:** Limited gliding during rotation of scapula or elevation and depression of clavicle.

# Shoulder Joint

- **Type:** Synovial ball-and-socket joint.
- **Articulation:** between the rounded head of the humerus and the shallow pear-shaped glenoid cavity of the scapula. Articular facets are covered with hyaline cartilage. **Glenoid labrum** increases the depth of the glenoid cavity.
- **Capsule:** is attached to the margin of the glenoid cavity (outside the labrum) and to the anatomical neck of the humerus. The capsule is lax (specially inferiorly) to give wide movement.
- **Ligaments:** (1) Weak glenohumeral, (2) transverse humeral and (3) Coracohumeral.

# Shoulder Joint

- **Accessory ligaments:** Coracoacromial ligament supports the joint from above.
- **Synovial membrane:** It lines all the joint cavity except the hyaline cartilage.
  - It surrounds the tendon of the long head of biceps brachii (intracapsular extrasynovial).
  - It communicates with the subscapularis bursa through a hole on the anterior wall of the capsule.
- **Nerve supply:**
  1. Axillary nerve.
  2. Suprascapular nerve.

# Movement of Shoulder Joint

1. **Flexion:** by pectoralis major, anterior fibers of deltoid, biceps brachii and coracobrachialis.
2. **Extension:** by latissimus dorsi, posterior fibers of deltoid and teres major.
3. **Adduction:** by pectoralis major, latissimus dorsi, teres major and teres minor.
4. **Abduction:** starts by supraspinatus and continues by deltoid.
5. **Medial rotation:** by pectoralis major, latissimus dorsi, teres major, anterior fibers of deltoid and subscapularis.
6. **Lateral rotation:** by infraspinatus, teres minor and posterior fibers of deltoid.

# Abduction of the Arm

1. **From 0° to 15°**: by supraspinatus muscle.
2. **From 15° to 90°** : by deltoid muscle.
3. **Above 90°** : by rotation of the scapula by trapezius and serratus anterior muscles.

**THANK YOU**