

بِسْمِ اللَّهِ الرَّحْمَنِ الرَّحِيمِ

BACK

Site of nuchal ligament

Spinal (posterior) part
of deltoid

Teres major

Latissimus dorsi

External oblique

Posterior median furrow

Gluteus medius

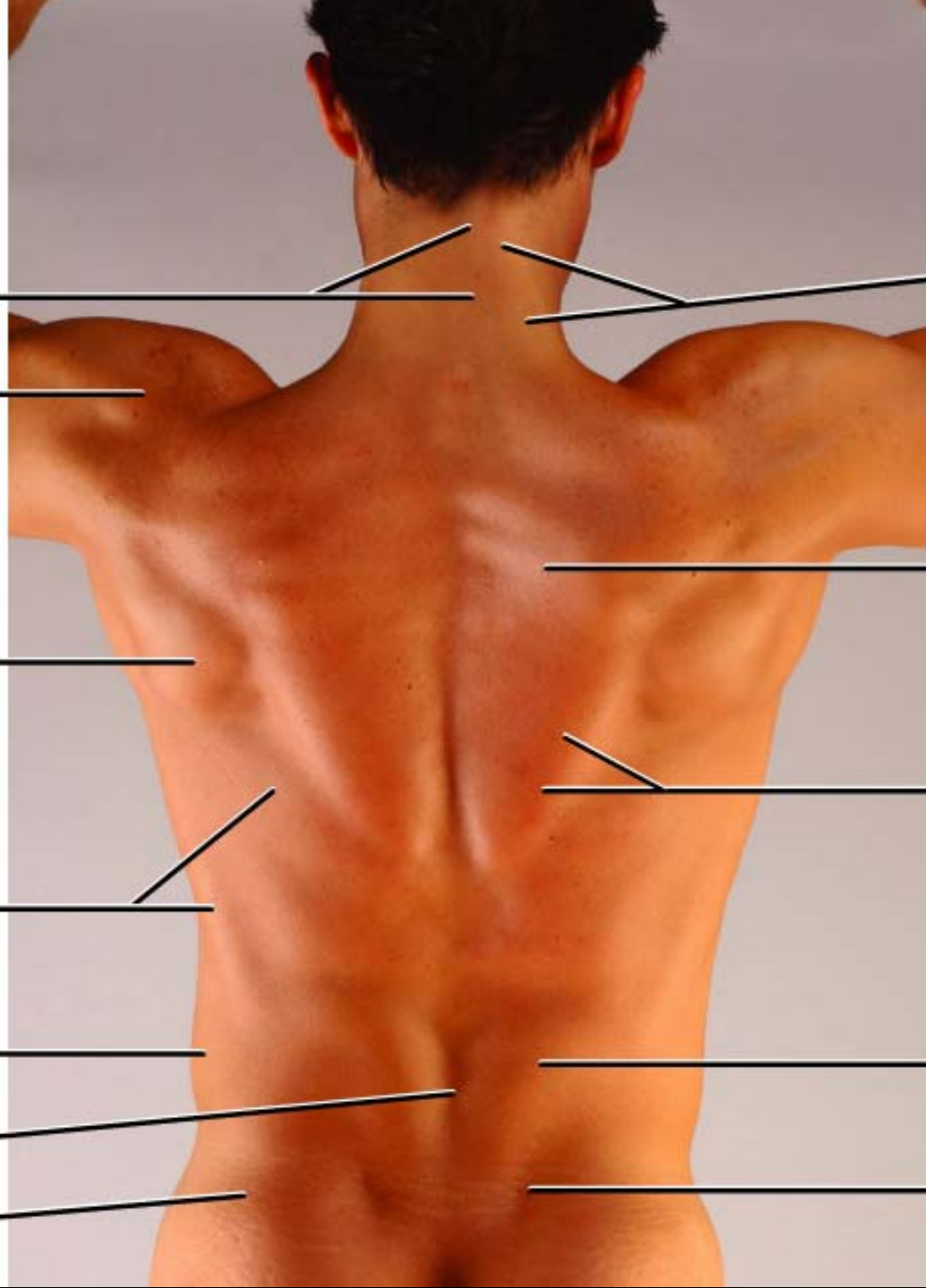
Descending (superior)
part of trapezius

Transverse (middle)
part of trapezius

Ascending (inferior)
part of trapezius

Erector spine

Site of posterior superior
iliac spine



Skin

- **Nerve supply**: by the dorsal rami of the spinal nerves.
- **Arterial supply**: branches from the posterior intercostal and lumbar arteries.
- **Venous Drainage**: to azygos vein and inferior vena cava.
- **Lymph Drainage**: to the posterior group of axillary lymph nodes.

Layers of Muscles

■ First Layer:

–Trapezius and latissimus dorsi.

■ Second Layer:

–Levator scapulae, rhomboid minor and rhomboid major.

■ Third Layer:

–Serratus posterior superior and serratus posterior inferior.

Trapezius

➤ Origin:

1. Medial third of superior nuchal line of occipital b.
2. External occipital protuberance.
3. Ligamentum nuchae.
4. Spine of the seventh cervical vertebra.
5. Spines and supraspinous ligaments of all thoracic vertebrae

➤ Insertion:

1. Upper fibers into the posterior aspect of the lateral third of the clavicle.
2. Middle fibers into the medial border of the acromion process of the scapula.
3. Lower fibers into the spine of the scapula.

Trapezius

➤ Nerve Supply:

- **Motor fibers** from the spinal part of accessory nerve.
- **Proprioceptive sensory fibers** from the third and fourth cervical nerves.

➤ Action:

- Upper fibers:** elevates the scapula.
- Middle fibers:** retracts the scapula.
- Lower fibers:** depresses the scapula.
- With serratus anterior:** rotates the scapula upward (for abduction of the arm more than 90°).
- When scapula is fixed:** both side muscles extend the head.

Latissimus dorsi

➤ Origin:

1. Spines of the lower 6 thoracic vertebrae.
2. Lower 3 or 4 ribs.
3. Lumbar fascia and posterior part of iliac crest.
4. Inferior angle of the scapula.

➤ Insertion:

Floor of the bicipital groove of the humerus.

➤ Nerve Supply:

Thoracodorsal nerve.

➤ Action:

- A. Adduction, extension and medial rotation of the arm.
- B. Climbing.

Levator scapulae

- **Origin:**
The transverse processes of the upper four cervical vertebrae.
- **Insertion:**
Dorsal lip of the medial border of the scapula above the level of its spine.
- **Nerve Supply:**
From the ventral rami of the 3rd and 4th cervical nerves and form dorsal scapular nerve (C5).
- **Action:**
 - A. Elevation of the scapula.
 - B. If the scapula is fixed, it bends the head to the same side.

Rhomboid minor

➤ Origin:

1. Lower part of ligamentum nuchae.
2. Spine of seventh cervical vertebra.
3. Spine of first thoracic vertebra.

➤ Insertion:

Dorsal lip of the medial border of the scapula opposite the root of its spine.

➤ Nerve Supply:

Dorsal scapular nerve (C5).

➤ Action:

- A. Elevation of the scapula.
- B. With rhomboid major and pectoralis minor, it rotates the scapula downward.

Rhomboid major

➤ Origin:

1. From 2nd to 5th spines of the thoracic vertebrae.
2. And their supraspinous ligaments.

➤ Insertion:

Dorsal lip of the medial border of the scapula below the level of its spine.

➤ Nerve Supply:

Dorsal scapular nerve (C5).

➤ Action:

- A. Elevation of the scapula.
- B. With rhomboid major and pectoralis minor, it rotates the scapula downward.

THANK YOU